

WANG, Ching-Jen; YANG, Kuender D. - Biological mechanism of musculoskeletal shockwaves. **ISMST Newsletter** [Em linha]. 1:1 (2006) 5–11. [Consult. 6 jan. 2015]. Disponível na Internet:<URL: http://www.shockwave.cc/e107_images/custom/sw-biological_mechanism_of_eswt.pdf

Notas prévias:

Produzido pelos Serviços de Biblioteca, Informação Documental e Museologia da Universidade de Aveiro.

Organização da paginação: topo da página, entre parêntesis retos.

As referências bibliográficas encontram-se numeradas sequencialmente no final do texto. Ao longo do texto esta numeração aparece referenciada, por vezes de forma repetida, entre parêntesis retos.

[5]

INTERNATIONAL SOCIETY FOR MUSCULOSKELETAL SHOCKWAVE THERAPY - ISMST NEWSLETTER

Biological Mechanism of Musculoskeletal Shockwaves

Ching-Jen Wang, MD (The Department of Orthopedic Surgery Chang Gung Memorial Hospital at Kaohsiung Taiwan), **Feng-Sheng Wang, PhD** (Medical Research Chang Gung Memorial Hospital at Kaohsiung Taiwan) **and Kuender D. Yang, MD, PhD** (Medical Research Chang Gung Memorial Hospital at Kaohsiung Taiwan)

Abstract

These studies were conducted to investigate the biological mechanism of musculoskeletal Shockwaves. The investigations were independently performed in tendon and bone, and at the tendon-bone interface in rabbits. The study limbs were treated with Shockwaves, whereas the control limbs received sham treatment with no shockwave. The evaluations included histomorphological examination, biomechanical analysis and immuno-histochemical assessments of angiogenic growth indicators including endothelial nitric oxide synthase (eNOS), vessel endothelial growth factor (VEGF), bone morphological protein (BMP-2) and proliferating cell nuclear antigen (PCNA).

The results showed higher bone strength and bone mass and better tensile strength of the graft at tendon-bone interface in the Shockwave group than the control group. Furthermore, Shockwave treatment significantly induced the ingrowth of neovascularization associated with increased expressions of angiogenic growth indicators in tendon and bone, and at the tendon-bone interface as compared with the control. The effects of shock waves appeared to be time-dependent as well as being dose-dependent.

In conclusion, extracorporeal shock waves produced consistent biological effects in tendon and bone, and at the tendon-bone interface. The biological mechanism of musculoskeletal Shockwaves appeared to stimulate the expressions of angiogenic growth factors and induce the ingrowth of neovascularization. Neovascularization may play a role in the improvement of blood supply and healing of tendon and bone.

Introduction

Extracorporeal shock wave has been shown to be effective for certain orthopedic conditions including non-union of long bone fracture,[1,2,3,4] calcifying tendonitis of the shoulder, [5,6,7,8,9] lateral epicondylitis of the elbow, [10,11,12,13] proximal plantar fasciitis and Achilles tendonitis. [17] In animal experiments, shockwaves also showed positive effects in promoting bone healing. [18,19,20,21] However, the exact mechanism of shockwave in musculoskeletal disorders remains unknown. The results of animal experiments demonstrated that shockwaves induced neovascularization at the tendon-bone junction. [22,23] We hypothesized that physical shockwaves might induce biological effects that lead to healing of tendons and bone. The purposes of the studies were to investigate the biological effects of shockwaves in tendon, bone and tendon-bone interface and to elucidate the biological mechanism of musculoskeletal shockwaves.

Materials and Methods

The approval of The Institutional Review Board was obtained. These studies were performed under the guidelines and the care and use of animals in research.

I. Experimental study in tendon

Fifty New Zealand white rabbits of 12 months old with body weight ranging from 2.5 to 3.5 Kg were used in this study. The right limbs (study side) received shockwave treatment to the Achilles tendon near the insertion to heel bone, while the left limbs (control side) received sham treatment with no shock waves. The source of shockwave was from an electrohydraulic OssaTron device (High Medical Technology, Kreuzlingen, Switzerland). The shockwave tube was focused on the Achilles tendon near the insertion, and the depth of the treatment was determined with the control guide of the machine and confirmed with C-arm image. Each of the study limbs received a single treatment of shockwave with 500 impulses at 14 kV (equivalent to 0.18 mJ/mm²). The shockwave dosage so selected was based on our previous experiences in animal studies. [21,22,23] The sham treatment was performed on the left limbs (control side) using a dummy electrode that did not generate acoustic waves with the impulses.

Histomorphological examination

Biopsies of the Achilles tendon-bone unit were performed in 0, 1, 4, 8 and 12 weeks with 10 rabbits at each time interval with the first biopsy obtained in 24 hours after shockwave application. The decalcified specimens were sectioned and stained with hematoxylin-eosin stain. The tissue distributions and the number of new blood vessels including capillary and muscularized vessel were examined microscopically.

Immunohistochemistry analysis

The angiogenic growth markers including vessel endothelial growth factor (VEGF) and endothelial nitric oxide synthase (eNOS) were examined to confirm the neovascularization, and proliferating cell nuclear antigen (PCNA) was chosen to reflect endothelial cell proliferation with immunohistochemistry stains. [21,25,26] The vessels showing positive VEGF expression and cells displaying positive PCNA and eNOS expressions were counted microscopically and the

numbers of cells and tissues with positive expression were quantitatively assessed.

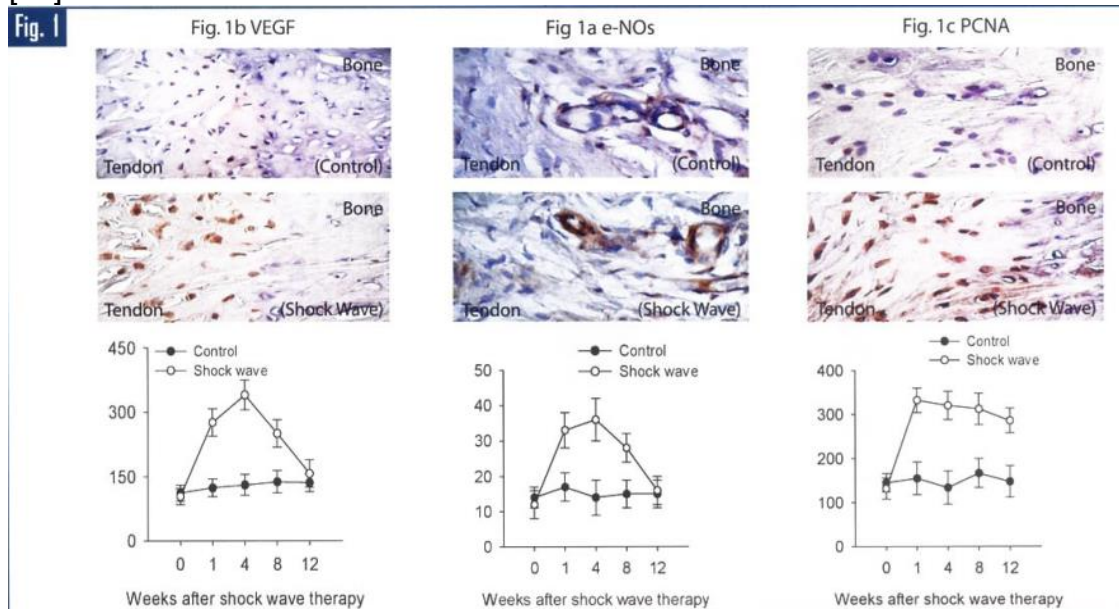
Results of biological response in tendon

The results of eNOS, VEGF and PCNA expressions and the number of neo-vessel of the study and the control sides are summarized in **Table 1**. In the study side, a significant increase in the number of neo-vessels was noted in 4 to 12 weeks, whereas no increase of neo-vessels was noted in the control side, and the difference was statistically significant. It appeared that the ingrowth of neo-vessels after shockwave treatment was time dependent. In the study side, significant, increases of eNOS, VEGF and PCNA were noted in as early as one week and lasted for 8 weeks before they declined to normal at 12 weeks, except PCNA increase lasted until 12 weeks (**Fig. 1**). In the control side, however, no significant changes in eNOS, VEGF and PCNA expressions were noted, and the differences between the study and control sides were statistically significant. It appeared that shockwaves stimulated the early release of eNOS, VEGF and PCNA expressions, and subsequent ingrowth of neo-vessels.

Nota de revisor: a seguir apresenta-se uma tabela constituída por 4 colunas e 26 linhas e que corresponde à **Table 1**. The results of eNOS, VEGF and PCNA expression and the number of neo-vessels in tendon. [23] Esta tabela é acompanhada pela seguinte legenda: P-values: Comparison of the control with the shock wave side was based on Mann-Whitney test. (40x magnification).

Time	Control (N=50) Mean ± SD	Shockwave (N=50) Mean ± SD	P-value
0-week (N=10)			
eNOS	112 ± 19	104 ± 21	0.57
VEGF	14 ± 3	12 ± 4	0.94
PCNA	145 ± 21	132 ± 24	0.75
Neo-vessel	22 ± 3	24 ± 4	0.93
1-week (N=10)			
eNOS	124 ± 21	293 ± 31	<0.001
VEGF	17 ± 4	33 ± 5	0.0068
PCNA	155 ± 37	332 ± 28	0.021
Neo-vessel	24 ± 4	26 ± 5	0.95
4-week (N=10)			
eNOS	131 ± 24	344 ± 32	<0.001
VEGF	14 ± 5	36 ± 6	0.0018
PCNA	134 ± 38	320 ± 32	0.011
Neo-vessel	22 ± 5	42 ± 4	0.024
8-week (N=10)			
eNOS	138 ± 26	265 ± 45	0.016
VEGF	15 ± 4	28 ± 4	0.034
PCNA	167 ± 33	312 ± 36	0.024
Neo-vessel	24 ± 5	40 ± 5	0.021
12-week (N=10)			
eNOS	136 ± 21	189 ± 42	0.71
VEGF	17 ± 5	16 ± 4	0.84
PCNA	154 ± 21	280 ± 28	0.034
Neo-vessel	25 ± 6	42 ± 4	0.017

Nota de revisor: a seguir apresenta-se uma imagem que corresponde à **Fig. 1** e cuja legenda é: In the study group, significant increases of eNOS, VEGF and PCNA noted in as early as one week and lasted for 8 weeks before they declined to normal at 12 weeks, except PCNA increase lasted until 12 weeks on immunohistochemical stains. In the control side, however, no significant changes in eNOS, VEGF and PCNA expressions were noted, and the differences between the study and control sides were statistically significant. [21]



[6]

II. Experimental study in bone

Twenty-four New Zealand white rabbits of 12 months old with body weight ranging from 2.7 kg to 3.6 kg were used in this study. A 1.5 mm Kirchnur pin was inserted retrograde into the canal of the femur through a mini-arthrotomy of the knee. A closed fracture of the right femur was created with a three-point bend method and was confirmed with radiographs. The rabbits were randomly divided into three groups with eight rabbits in each group. The first group (the control) received sham treatment with no shock wave. The second group received low-energy shock wave with 2000 impulses at 14 kV (equivalent to 0.18 mJ/mm² energy flux density). The third group received high-energy shock wave with 4000 impulses at 14 KV. Shock waves were applied in one week after the operation when the surgical wounds had healed. The location of the fracture site and the depth of the treatment were confirmed with the control guide of the machine and C-arm imaging. The sham treatment was performed with a dummy electrode that did not generate acoustic waves with the impulses.

Radiographs of the right femur in A-P and lateral views were performed in [1,4,8] and 12 weeks. The fracture healing was evaluated with clinical assessment and confirmed with radiographic examination.

Biomechanical examination

The animals were sacrificed at 12 weeks, and a 5-cm long femur bone including the callus was harvested. The specimens were subject to

biomechanical testing on Material Testing System (MTS, Minneapolis, MN) including peak load, peak stress and modulus of elasticity. The biomechanical testing was similarly performed in high-energy, low-energy and control groups.

[7]

Histomorphological examination

After biomechanical testing, the specimens were decalcified and sectioned and subject to hematoxylin-eosin, alcian blue or alizarin red stains (Sigma Chemicals Inc, St. Louis, MO, USA) for the purpose of distinguishing fibrous tissue, cartilaginous and bony tissues within the region of interest.

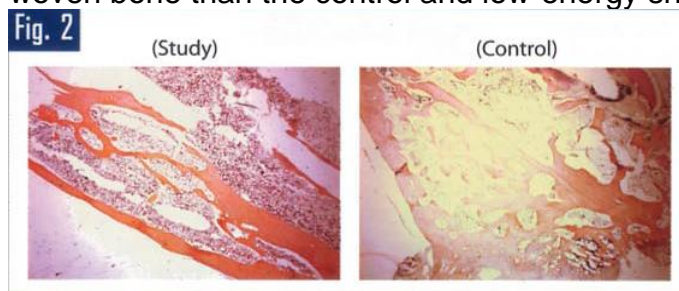
Immunohistochemical examination

The angiogenic activities including eNOS, VEGF, BMP-2 and PCNA were examined with immunohistochemistry stains for verification of neo-vessels. The specimens were immunostained for eNOS, VEGF, BMP-2 and PCNA (Santa Cruz Biotechnolog Inc, CA, USA). An antibody against von Willebrand factor (vWF) was used to identify the immunolocalization of neo-vessels in the fracture sites. The number of positive immuno-labeled cells and total cells in each area were counted and the percentage of positive labeled cells was calculated.

Results of biological response in bone

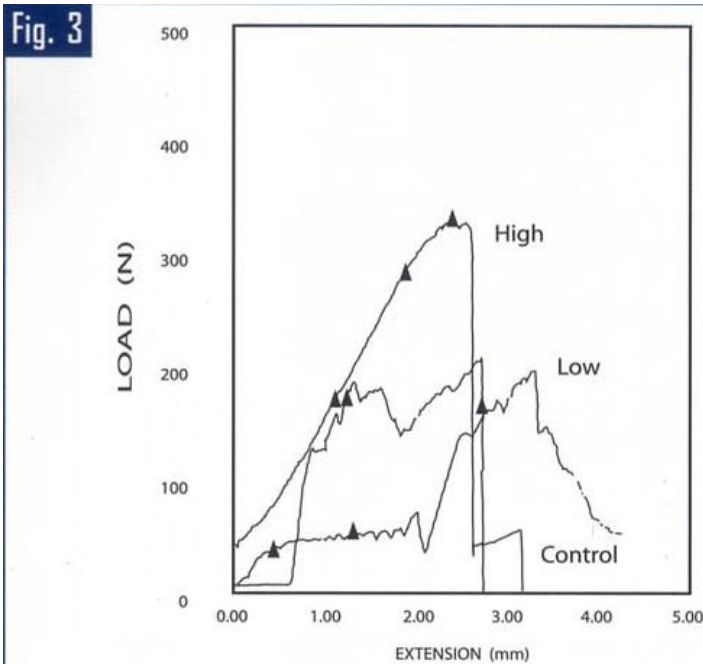
The histomorphological features showed that high-energy shock waves produced significantly more cortical bone, less fibrous tissue and comparable woven bone than the control and low-energy shock waves (**Fig. 2**). The results of low-energy shock wave did not differ significantly from the control group.

Nota de revisor: a seguir apresenta-se uma imagem que corresponde à **Fig. 2** e cuja legenda é: Histomorphology showed that high-energy shock waves produced significantly more cortical bone, less fibrous tissue and comparable woven bone than the control and low-energy shock waves. [39]



The results of biomechanical study showed that high-energy shock waves demonstrated better bone strength including peak load, peak stress and modulus of elasticity than low-energy shock wave and the control (**Fig. 3**). The low-energy shock waves showed comparable results as compared with the control.

Nota de revisor: a seguir apresenta-se uma imagem que corresponde à **Fig. 3** e cuja legenda é: Biomechanical testing showed that high-energy shock waves demonstrated belter bone strength including peak load, peak stress and modulus of elasticity than low-energy shock waves and the control. The low-energy shock waves showed comparable results as compared with the control. [39]



The results of positive eNOS, BMP-2, VEGF and PCNA immunostained cells and the numbers of neo-vessels in the fracture sites of the control, low- and high-energy groups are summarized in **Table 2**. The numbers of neo-vessels and cells with positive eNOS, BMP-2, VEGF and PCNA expressions are significantly higher in high-energy Shockwave group than the control and low-energy groups (**Fig. 4**). The data of the low-energy group did not differ significantly from the control group. The biological effects of Shockwaves appeared to be dose-dependent.

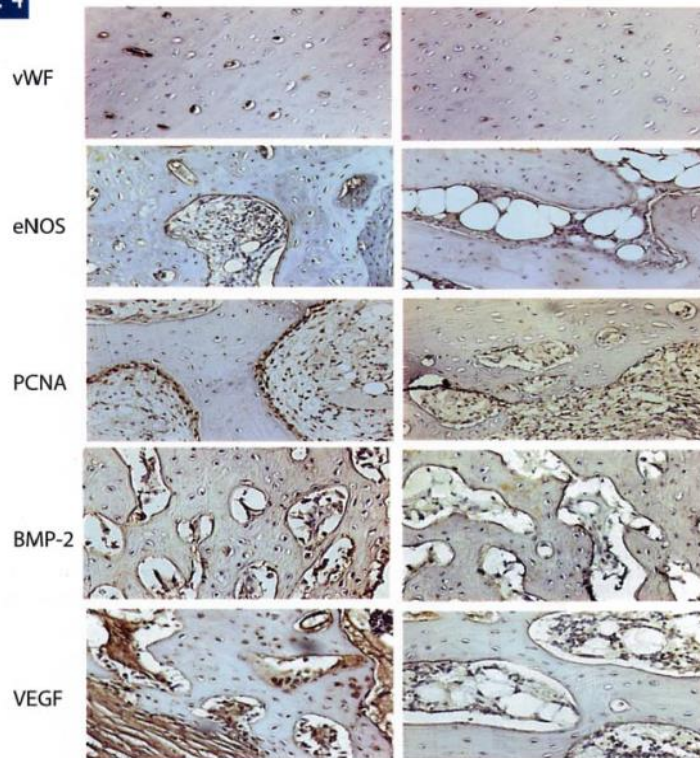
Nota de revisor: a seguir apresenta-se uma tabela constituída por 4 colunas e 16 linhas e que corresponde à **Table 2**. The results of positive eNOS, VEGF, BMP and PCNA immunostained cells and the number of neo-vessels in bone. Esta tabela é acompanhada pela seguinte legenda: The data were analyzed using a general linear model followed by a Duncan's multiple range of test to determine the significance between treatments. (40x magnification). P-value 1: comparison of the control with low- and high-energy groups. P-value 2: comparison of low-energy with high-energy groups.

Shock waves	Control N = 8 Mean ± SD	Low-energy N = 8 Mean ± SD	High-energy N = 8 Mean ± SD
Neo-vessel and growth indicator			
BMP-2	211 ± 21	207 ± 28	348 ± 19
P-value 1	[sem informação]	0.74	0.015
P-value 2	[sem informação]	[sem informação]	0.026
eNOS	179 ± 16	192 ± 18	272 ± 21
P-value 1	[sem informação]	0.89	0.026
P-value 2	[sem informação]	[sem informação]	0.014
VEGF	168 ± 20	186 ± 20	257 ± 21
P-value 1	[sem informação]	0.62	0.036
P-value 2	[sem informação]	[sem informação]	0.024
PCNA	196 ± 26	213 ± 18	306 ± 21
P-value 1	[sem informação]	0.87	<0.01
P-value 2	[sem informação]	[sem informação]	0.017

Neo-vessels	37 ± 10	43 ± 12	78 ± 17
P-value 1	[sem informação]	0.72	0.012
P-value 2	[sem informação]	[sem informação]	0.006

Nota de revisor: a seguir apresenta-se uma imagem que corresponde à **Fig. 4** e cuja legenda é: The numbers of neo-vessels and cells with positive eNOS, BMP-2, VEGF and PCNA expressions are significantly higher in high-energy shock wave group than the control group.

Fig. 4



[8]

III. Experimental study in tendon-bone interface

Thirty-six New Zealand white rabbits of 12 months old with body weight ranging from 2.79 Kg to 3.65 Kg were used in this study. Arthrotomy of the knee was carried out and the anterior cruciate ligament (ACL) was excised. The long digital extensor tendon was dissected off distally at the musculotendinous junction while the proximal end was left intact. A tibia tunnel was created with a graft size-matched drill bit. The distal end of the graft was pulled through the tibia tunnel to complete ACL reconstruction.

Shockwave application

The left knees received sham treatment with no shock wave, and were used as the control group. The right knees received Shockwave treatment immediately after surgery, and were regarded as the study group. The shockwave tube was focused on the mid-portion of the tibia tunnel with the control guide of the device, and the depth was estimated clinically and determined with an ultrasound guide. Each knee was treated with 500 impulses of shockwaves at 14 kV (equivalent to 0.18 mJ/mm²) to the right knee. In sham

treatment, a dummy electrode was used that no acoustic waves were generated with the impulses.

Histomorphological Studies

Twenty-four rabbits were sacrificed at different time intervals with 4 rabbits each at 1, 2, 4, 8, 12 and 24 weeks. The central portion of the proximal tibia including the tendon graft was harvested. The specimens were decalcified, sectioned and stained with hematoxylin-eosin stain. The distributions of the tissues surrounding tendon graft and the bonding of trabecular bone to tendon were examined microscopically.

Biomechanical examination

Twelve rabbits were sacrificed at 12 and 24 weeks with 6 rabbits at each time interval. The ligament structures of the knee were removed and only the ACL graft was retained. The tensile strength of the graft was measured with slow load distraction curve on Material Testing Machine (MTS, Minneapolis, MN). The pullout strength, the failure load and the modes of failure were analyzed.

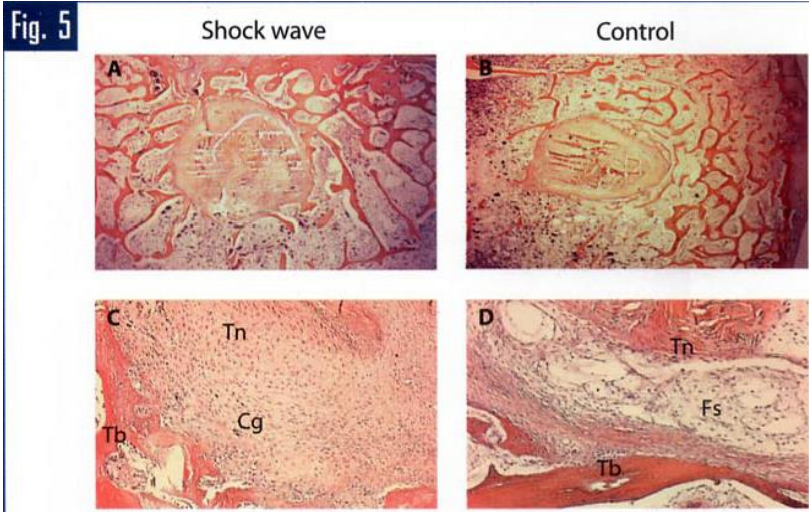
Immunohistochemical examination

The decalcified specimens were cut into sections in longitudinal and axial directions. Sections were immunostained for eNOS, VEGF, BMP-2 and PCNA (Santa Cruz Biotechnology Inc, CA, USA) for the purpose of identifying angiogenic growth indicators. An antibody against von Willebrand factor (vWF) was used to identify the immunolocalization of neo-vessels. The numbers with positive expression were quantitatively assessed.

Results of biological response in tendon-bone interface

The trabecular bone in the surrounding tissues of the tendon graft increased significantly with time in the study group ($P < 0.05$), whereas, the changes in the control group were statistically not significant ($P > 0.05$). The difference in the amount of trabecular bone around the tendon graft between the study and control groups was statistically significant after 4 weeks. The bonding between tendon and bone was much more intimate in the study group than the control group, and the difference in the percentage of bonding between tendon and bone was statistically significant between the study and control groups ($P < 0.05$) (**Fig. 5**).

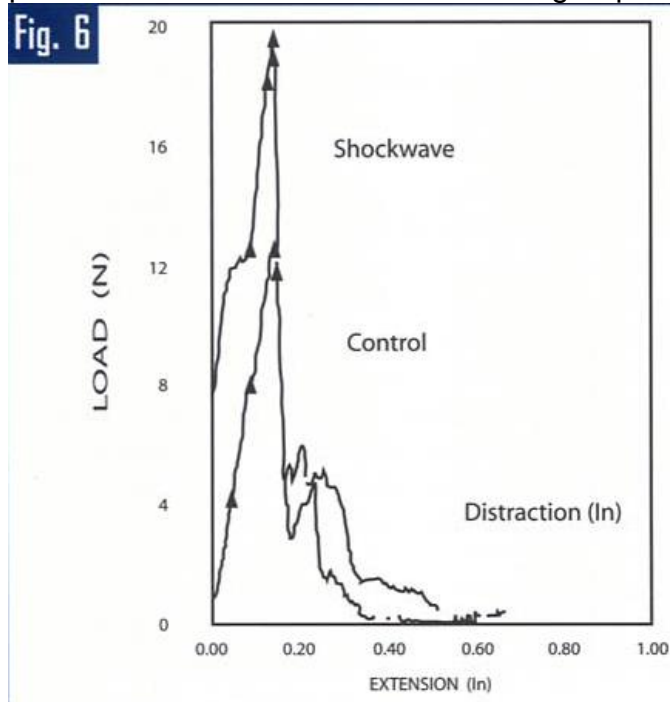
Nota de revisor: a seguir apresenta-se uma imagem que corresponde à **Fig. 5** e cuja legenda é: The trabecular bone surrounding the tendon graft increased significantly in the shock wave group as compared with the control group. The bonding between tendon and bone was much more intimate in the study group than the control. [37]



[9]

The biomechanical testing showed that higher tensile strength of the graft and better pullout failure load noted in the Shockwave group than the control group (**Fig. 6**).

Nota de revisor: a seguir apresenta-se uma imagem que corresponde à **Fig. 6** e cuja legenda é: Biomechanical testing showed higher tensile strength and better pull-out failure load in the shock wave group than the control group. [37]

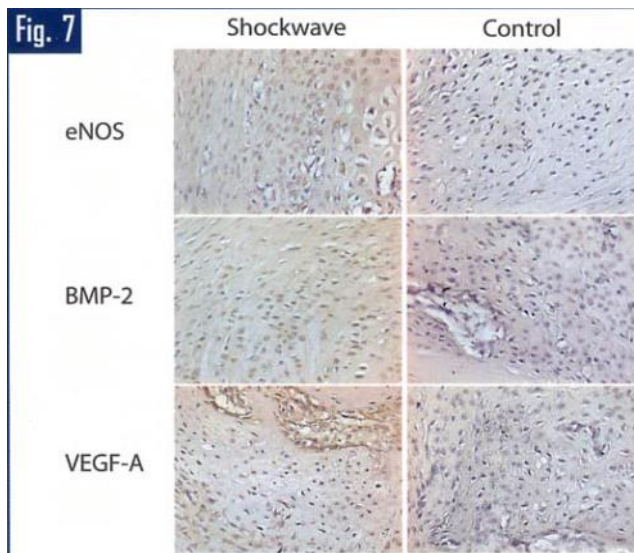


The results of eNOS, VEGF, PCNA and BMP-2 expressions and the number of neo-vessels at the tendon-bone interface at different time intervals are summarized in **Table 3**. The numbers of neo-vessels and the cells with positive immunostain are significantly higher in the Shockwave group than the control group, and the difference was statistically significant at different time intervals (**Fig. 7**).

Nota de revisor: a seguir apresenta-se uma tabela constituída por 5 colunas e 31 linhas e que corresponde à **Table 3**. The results of eNOS, VEGF-A, PCNA and BMP-2 expressions and the number of neo-vessels in tendon-bone interface. Esta tabela é acompanhada pela seguinte legenda: P-values were based on Mann-Whitney test. (40x magnification)

Time	Growth indicator	Shockwave Mean \pm SD	Control Mean \pm SD	P-value
1-week (N=3)	eNOS	256 \pm 21	112 \pm 18	<0.001
	VEGF-A	246 \pm 36	228 \pm 25	0.82
	PCNA	122 \pm 15	123 \pm 17	0.63
	BMP-2	89 \pm 11	94 \pm 13	0.58
	Neo-vessels	47 \pm 9	41 \pm 2	0.534
2-weeks (N=3)	eNOS	224 \pm 24	106 \pm 18	0.006
	VEGF-A	389 \pm 42	254 \pm 27	0.014
	PCNA	234 \pm 21	138 \pm 19	0.023
	BMP-2	143 \pm 22	98 \pm 17	0.014
	Neo-vessels	53 \pm 12	46 \pm 13	0.619
4-weeks (N=3)	eNOS	202 \pm 20	108 \pm 21	0.016
	VEGF-A	432 \pm 41	268 \pm 32	0.002
	PCNA	278 \pm 26	143 \pm 21	0.016
	BMP-2	184 \pm 24	104 \pm 16	0.007
	Neo-vessels	82 \pm 14	52 \pm 11	0.017
8-weeks (N=3)	eNOS	142 \pm 18	122 \pm 25	0.14
	VEGF-A	452 \pm 37	276 \pm 28	0.004
	PCNA	316 \pm 23	149 \pm 19	0.022
	BMP-2	212 \pm 21	98 \pm 15	<0.001
	Neo-vessels	93 \pm 15	47 \pm 9	<0.01
12-weeks (N=6)	eNOS	123 \pm 19	108 \pm 23	0.57
	VEGF	463 \pm 26	284 \pm 26	0.013
	PCNA	308 \pm 21	158 \pm 25	0.017
	BMP-2	168 \pm 24	106 \pm 18	0.023
	Neo-vessels	87 \pm 14	44 \pm 12	0.0085
24-weeks (N=6)	eNOS	132 \pm 23	98 \pm 19	0.68
	VEGF	476 \pm 31	271 \pm 25	<0.001
	PCNA	312 \pm 28	154 \pm 17	<0.001
	BMP-2	152 \pm 27	115 \pm 16	0.026
	Neo-vessels	86 \pm 12	47 \pm 12	0.0046

Nota de revisor: a seguir apresenta-se uma imagem que corresponde à **Fig. 7** e cuja legenda é: The numbers cells with positive immunostain for eNOS, BMP-2 and VEGF-A at the tendon-bone interface are significantly higher in the shock wave group than the control group. [37]



Discussion

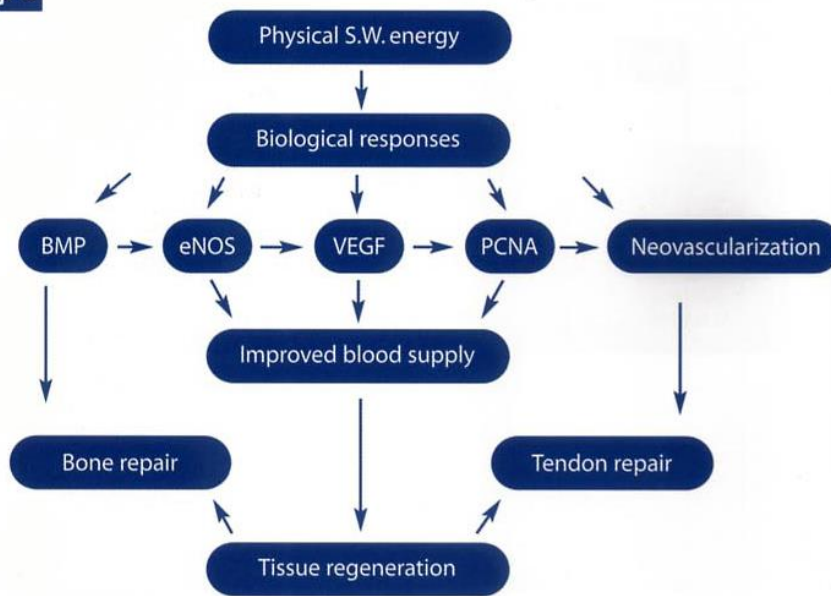
Some authors speculated that Shockwaves relieved pain due to insertional tendinopathy by hyper-stimulation analgesia and increase of pain threshold. [28] Other authors hypothesized the mechanism of microfracture including micro-disruption of avascular or minimally vascular tissue to encourage revascularization and the recruitment of appropriate stem cells conducive to bone healing. [27,28] However, there are insufficient data to scientifically substantiate either theory concerning the mechanism of Shockwaves in musculoskeletal disorders. Many recent studies in animal experiments demonstrated the modulation of Shockwave including neovascularization, osteogenic differentiation of mesenchymal stem cell and release of osteogenic and angiogenic growth factors. [22,23,29,37] Therefore, extracorporeal Shockwaves produced effects of tissue regeneration and/or repair in musculoskeletal tissues, rather than a mechanical disintegration.

[10]

Many studies demonstrated that over-expressions of eNOS and VEGF induced angiogenesis. [24,25] The results of the current studies demonstrated for the first time that mechanical shockwaves stimulated the ingrowth of neovascularization associated with increased expressions of angiogenic growth markers including eNOS, VEGF and PCNA in tendon, bone and tendon-bone interface. Neovascularization may play a role to improve blood supply and healing of tendon and bone. Rompe et al [38] reported a dose related effects of shockwave on rabbit tendon Achilles. Wang et al [39] demonstrated that shockwave treatment showed dose-dependent enhancement of bone mass and bone strength after fracture of the femur. The results of these studies showed that the effect of shockwave in musculoskeletal tissues appeared to be time-dependent as well as being dose-dependant. Therefore, it seemed likely that physical shockwaves raised the mechanotransduction and converted into biological signals that lead to a cascade of biological responses in tendon, bone and tendon-bone interface (**Fig. 8**).

Nota de revisor: a seguir apresenta-se uma imagem que corresponde à **Fig. 8** e cuja legenda é: A proposed cascade of biological mechanism of extracorporeal shock waves in musculoskeletal tissues.

Fig. 8



Conclusion

The biological mechanism of musculoskeletal Shockwaves appeared to initially stimulate the expressions of angiogenic growth factors, and subsequently the ingrowth of neovascularization and improvement in blood supply that lead to repair of tendon and bone. Musculoskeletal shockwaves produced consistent biological effects in tendon and bone and at the tendon-bone interface. In contrast to lithotripsy where shockwaves are used to disintegrate urolithiasis, shockwaves in orthopedics (orthotripsy) are not been used to disintegrate tissues, but rather to microscopically cause interstitial and extracellular biological effects including tissue regeneration.

Acknowledgement

These studies were partially or totally supported by grants. The sources of grants are from Chang Gung Research Fund (CMRP 83001) and National Science Council (NSC91-2314-B-182A-068). No fund was received or will be received from a commercial party directly or indirectly related to the subjects of this article.

The authors like to thank Ya-Zu Yang, Yi-Chi Sun and Ya-Hsieh Chuang for their technical assistances and collection of data in the studies.

References

1. Haupt G. Use of extracorporeal shock wave therapy in the treatment of pseudoarthrosis, tendinopathy and orthopaedic disease. *J Urology* 1997; 158:4-11.
2. Rompe JD, Rosendahl T, Schöllner C, et al. High-energy extracorporeal shock wave treatment of nonunions. *Clin Orthop* 2001; 387: 102-111.
3. Schaden W, Fischer A and Sailler A. Extracorporeal shock wave therapy of nonunion or delayed osseous union. *Clin Orthop* 2001; 387: 90-94.

4. Wang CJ, Chen HS, Chen CE, et al. Treatment of nonunions of long bone fractures with shock waves. *Clin Orthop* 2001; 387: 95-101.
5. Loew M, Daecke W, Kuznierczak D, et al. Shock-wave therapy is effective for chronic calcifying tendonitis of the shoulder. *J Bone Joint Surg* 1999; 81B:863-867.
6. Rompe JD, Rumler F, Hopf C, et al. Extracorporeal shock wave therapy for calcifying tendinitis of the shoulder. *Clin Orthop* 1995; 321:196-201.
7. Speed CA, Richards C, Nichols D, Burnet S, Wiles JT, Humphrey H, Hazlemann BL. Extracorporeal shock wave therapy for tendonitis of the rotator cuff. A double-blind, randomized, controlled trial. *J Bone Joint Surg. (Br)* 2002; 84: 509-12
8. Wang CJ, Ko JY, Chen HS. Treatment of calcifying tendonitis of the shoulder with shock wave therapy. *Clin Orthop* 2001;387: 83-89.
9. Wang CJ, Yang KD, Wang FS. Shock wave therapy for calcifying tendinitis of the shoulder. A two- to four-year follow-up. *Am J Sports Med* 2003; 31(3):425-30.
10. Hammer DS, Rupp S, Ensslin S, et al. Extracorporeal shock wave therapy in patients with tennis elbow and painful heel. *Arch Orthop Trauma Surg* 2000; 120:304-307.
11. Ko JY, Chen HS, Chen LM. Treatment of lateral epicondylitis of the elbow with shock waves. *Clin Orthop* 2001; 387:60-67.
12. Rompe JD, Hopf C, Kullmer K, et al. Analgesic effect of extracorporeal shock wave therapy on chronic tennis elbow, *J Bone Joint Surg* 1996; 78B: 23-237.
13. Speed CA, Nichols D, Richards C, Humphrey SH, Wiles JT, Burnet S, Hazlemann BL. Extracorporeal shock wave therapy for lateral epicondylitis - a double-blind, randomized, controlled trial. *J Orthop Res.* 2002; 20: 895-8.
14. Chen HS, Chen LM, Huang TW. Treatment of painful heel syndrome with shock waves. *Clin Orthop* 2001; 387: 41-46.

[11]

15. Ogden JA, Alvarez R, Levitt R, et al. Shock wave therapy for chronic proximal plantar fasciitis. *Clin Orthop* 2001;387:47-59.
16. Rompe JD, Hopf C, Nafe B, et al. Low-energy extracorporeal shock wave therapy for painful heel: A prospective controlled single-blind study. *Arch Orthop Trauma Surg* 1996; 115:75-79.
17. Perlick L, Schiffmann R, Kraft CN, Wallny T, Diedrich O. Extracorporeal shock wave treatment of the Achilles tendonitis: Experimental and preliminary clinical results. *Z Orthop Ihre Grenzgeb* 2002; 140(3): 275-80.
18. Delius M, Draenert K, Al Diek Y, et al. Biological effect of shockwave: In vivo effect of high-energy pulses on rabbit bone. *Ultrasound Med Biol* 1995; 21:1219-1225.
19. Johannes EJ, Kaulesar-Sukul DM, Metura E, et al. High-energy shock waves for the treatment of nonunions: An experiment on dogs. *J Surg Res* 1994; 57:246-254.
20. Kaulesar Sukul DM. Johannes EJ. Pierik EG. van Eijck GJ. Kristelijin MJ. The effect of high-energy shock waves focused on cortical bone: An in vitro study. *J Surg Res* 1993; 54: 46-51.

- 21.** Wang CJ, Huang HY, Chen HH, et al. Effect of shock wave therapy on acute fractures of the tibia. A study in a dog model. *Clin Orthop* 2001;387: 112-118.
- 22.** Wang CJ, Huang HY, Pai CH: Shock wave therapy enhanced neovascularization at the tendon-bond junction: an experiment in dogs. *J Foot Ankle Surg* 2002; 41: 16-22.
- 23.** Wang CJ, Yang KD, Wang FS, Huang CC, Yang LJ. Shock wave induces neovascularization at the tendon-bone junction. A study in rabbits. *J Orthop Res* 2003; 21:984-989.
- 24.** Babaei S, Stewart DJ. Overexpression of endothelial NO synthase induces angiogenesis in a co-culture model. *Cardiovascular Res.* 2002; 55: 190-200.
- 25.** Spyridopoulos I, Luedeman C, Chen D, Kearney M, Murohara T, Principe N, Isner M, Losordo DW. Divergence of angiogenesis and vascular permeability signaling by VEGF: inhibition of protein kinase C suppresses VEGF-induced angiogenesis, but promotes VEGF-induced NO-dependent vascular permeability. *Arteriosclero, Thrombo and Vas Biol* 2002; 22: 901-6.
- 26.** Nagashima M, Tanaka H, Takahashi A, Tanaka K, Ishiwata T, Asano G, Yoshino S. Study of the mechanism involved in angiogenesis and synovial cell proliferation in human synovial tissues of patients with rheumatoid arthritis using SCID mice. *Lab Invest* 2002; 82(8): 981-8.
- 27.** Ogden JA, Toth -Kischkat A, Schultheiss R. Principles of shock wave therapy. *Clin Orthop* 2001; 387: 8-17.
- 28.** Thiel M: Application of shock waves in medicine. *Clin Orthop* 2001; 387:
- 29.** McCormack D, Lane H, McElwain J. The osteogenic potential of extracorporeal shock wave therapy: An in-vivo study. *Ir J Med Sci* 1996; 165:20-22.
- 30.** Maier M, Milz S, Wirtz DC, Rompe JD, Schmitz C. Basic research of applying extracorporeal Shockwaves on the musculoskeletal system. An assessment of current status. *Orthop* 2002; 31:667-77.
- 31.** McCormack D, Lane H, McElwain J. The osteogenic potential of extracorporeal shock wave therapy: An in vivo study. *Irish J Med Sci* 1996; 165: 20-22.
- 32.** Wang FS, Wang CJ, Sheen-Chen SM et al. Superoxide mediates shock wave induction of RRE-dependent osteogenic transcription factor (CBFA 1) and mesenchymal cells differentiation toward osteoprogenitors. *J Biol Chem* 2002; 277: 10931-7
- 33.** Wang FS, Yang KD, Wang CJ, et al. Extracorporeal shock wave promotes bone marrow stromal cell growth and differentiation toward osteoprogenitors associated with TGF-b 1 induction. *J Bone Joint Surg* 2002; 84B: 457-61.
- 34.** Wang FS, Wang CJ, Huang HC, et al. Physical shock wave mediates membrane hyperpolarization and Ras activation for osteogenesis in human bone marrow stromal cells. *Biochemical Biophysical Research Communications* 2001; 287: 648-655.
- 35.** Wang FS, Yang KD, Kuo YR, Wang CJ, Huang H.J, Chen YJ. Temporal and spatial expression of bone morphogenetic proteins in extracorporeal shock wave-promoted healing of fracture defect. *Bone* 2003; 32:387-396.
- 36.** Yang C, Heston WDW, Gulati S, Fair WR. The effect of high-energy shock waves (HESW) on human bone marrow. *Urol Res* 1988; 16:427-42.

- 37.** Wang CJ, Wang FS, Yang KD, Weng LS, Sun YC, Yang YL. The effect of shock wave treatment at the tendon-bone interface - A histomorphological and biomechanical study in rabbits. J Orthop Res 2004 (In press).
- 38.** Rompe JD, Kirkpatrick CJ, Küllmer K, et al. Dose related effects of shock waves on rabbit tendon Achilles. A sonographic and histological study. J Bone Joint Surg 1998; 80B: 546-552.
- 39.** Wang CJ, Yang KD, Wang FS, Hsu CC, Chen HS. Shock wave treatment shows dose-dependent enhancement of bone mass and bone strength after fracture of the femur. Bone 2004; 34:225-230.

REPRINT REQUEST AND CORRESPONDENCE TO:

Ching-Jen Wang, M.D.

Department of Orthopedic

Surgery Chang Gung Memorial

Hospital at Kaohsiung

123 Ta-Pei Road, Niao-Sung Hsiang

Kaohsiung, Taiwan 833

Tel: 886-7-733-5279; Fax: 886-7-733-5515

E-mail: w281211@adm.cgmh.org.tw

Running title: Biological mechanism of musculoskeletal Shockwaves.